European Journal of Nuclear Medicine and Molecular Imaging (2018) 45:1884–1897
https://doi.org/10.1007/s00259-018-4058-4

ORIGINAL ARTICLE

Prospective comparison of ^{68}Ga-PSMA PET/CT, ^{18}F-sodium fluoride PET/CT and diffusion weighted-MRI at for the detection of bone metastases in biochemically recurrent prostate cancer

Helle D. Zacho[1,2] · Julie B. Nielsen[1,2] · Ali Afshar-Oromieh[3,4] · Uwe Haberkorn[3,5] · Nandita deSouza[6] · Katja De Paepe[6] · Katja Dettmann[7] · Niels C. Langkilde[8] · Christian Haarmark[9] · Rune V. Fisker[1,10] · Dennis T. Arp[11] · Jesper Carl[12] · Jørgen B. Jensen[7,13] · Lars J. Petersen[1,2]

Received: 3 April 2018 / Accepted: 23 May 2018 / Published online: 6 June 2018
© Springer-Verlag GmbH Germany, part of Springer Nature 2018

Abstract

Purpose To prospectively compare diagnostic accuracies for detection of bone metastases by ^{68}Ga-PSMA PET/CT, ^{18}F-NaF PET/CT and diffusion-weighted MRI (DW_{600}-MRI) in prostate cancer (PCa) patients with biochemical recurrence (BCR).

Methods Sixty-eight PCa patients with BCR participated in this prospective study. The patients underwent ^{68}Ga-PSMA PET/CT, a ^{18}F-NaF PET/CT and a DW_{600}-MRI (performed in accordance with European Society of Urogenital Radiology guidelines, with b values of 0 and 600 s/mm^2). Bone lesions were categorized using a three-point scale (benign, malignant or equivocal for metastases) and a dichotomous scale (benign or metastatic) for each imaging modality by at least two experienced observers. A best valuable comparator was defined for each patient based on study-specific imaging, at least 12 months of clinical follow-up and any imaging prior to the study and during follow-up. Diagnostic performance was assessed using a sensitivity analysis where equivocal lesions were handled as non-metastatic and then as metastatic.

Results Ten of the 68 patients were diagnosed with bone metastases. On a patient level, sensitivity, specificity and the area under the curve (AUC) by receiver operating characteristic analysis were, respectively, 0.80, 0.98–1.00 and 0.89–0.90 for ^{68}Ga-PSMA PET/CT ($n = 68$ patients); 0.90, 0.90–0.98 and 0.90–0.94 for ^{18}NaF PET/CT ($n = 67$ patients); and 0.25–0.38, 0.87–0.92 and 0.59–0.62 for DW_{600}-MRI ($n = 60$ patients). The diagnostic performance of DW_{600}-MRI was significantly lower than that of ^{68}Ga-PSMA PET/CT and ^{18}NaF PET/CT for diagnosing bone metastases ($p < 0.01$), and no significant difference in the AUC was seen between ^{68}Ga-PSMA PET/CT and ^{18}NaF PET/CT ($p = 0.65$).

Electronic supplementary material The online version of this article (https://doi.org/10.1007/s00259-018-4058-4) contains supplementary material, which is available to authorized users.

✉ Helle D. Zacho
h.zacho@rn.dk

[1] Department of Nuclear Medicine and Clinical Cancer Research Center, Aalborg University Hospital, Hobrovej 18-22, Postboks 365, DK-9100 Aalborg, Denmark

[2] Department of Clinical Medicine, Aalborg University, Aalborg, Denmark

[3] Department of Nuclear Medicine, University Hospital Heidelberg, Heidelberg, Germany

[4] Department of Nuclear Medicine, Bern University Hospital, Bern, Switzerland

[5] Clinical Cooperation Unit Nuclear Medicine, DKFZ, Heidelberg, Germany

[6] The Institute of Cancer Research and Royal Marsden NHS Foundation Trust, London, UK

[7] Department of Urology, Regional Hospital West Jutland, Holstebro, Denmark

[8] Department of Urology, Aalborg University Hospital, Aalborg, Denmark

[9] Department of Clinical Physiology and Nuclear Medicine, Herlev and Gentofte Hospital, Herlev, Denmark

[10] Department of Radiology, Aalborg University Hospital, Aalborg, Denmark

[11] Department of Medical Physics, Oncology Department, Aalborg University Hospital, Aalborg, Denmark

[12] Department of Oncology, Naestved Sygehus, Zealand University Hospital, Roskilde, Denmark

[13] Department of Clinical Medicine, Aarhus University, Aarhus, Denmark

Conclusion ^{68}Ga-PSMA PET/CT and ^{18}F-NaF PET/CT showed comparable and high diagnostic accuracies for detecting bone metastases in PCa patients with BCR. Both methods performed significantly better than DW_{600}-MRI, which was inadequate for diagnosing bone metastases when conducted in accordance with European Society of Urogenital Radiology guidelines.

Keywords PSMA-PET/CT · NaF-PET/CT · Diffusion-weighted MRI · Bone metastases · Prostate cancer

Introduction

Biochemical recurrence (BCR) can occur in up to 40% of patients after curatively intended treatment for prostate cancer (PCa) [1]. According to the European Association of Urology (EAU) guidelines, bone scintigraphy should not be used in BCR until prostate-specific antigen (PSA) levels reach 10 ng/mL due to the supposed inadequate sensitivity of bone scintigraphy when PSA levels are low [2, 3]. However, detection of bone metastases even at very low PSA values is of paramount importance because the presence of bone metastases changes the treatment strategy [2] and prognosis [4, 5].

Over the last 5 years, ^{68}Ga-labelled prostate-specific membrane antigen (^{68}Ga-PSMA) PET/CT has gained widespread use to assess the sites of PCa recurrence [6, 7]. This method is able to identify metastatic lesions in the prostatic bed, lymph nodes, bones and soft tissue in one single investigation at low PSA levels [6, 8, 9]. In retrospective studies, ^{68}Ga-PSMA PET/CT shows encouraging diagnostic accuracy for detection of bone metastases compared to bone scintigraphy at the time of staging and in patients with BCR [10]. ^{18}F-sodium fluoride (^{18}F-NaF) PET/CT also evaluates the skeletal system with a high sensitivity and relatively good specificity owing to a high lesion-to-background ratio [11, 12]. Finally, MRI with diffusion-weighted imaging (DW-MRI) has been increasingly proposed as a method for visualizing the skeleton without the need for injecting radioactive tracers. Its accuracy in assessing bone has been shown to be high on the basis of early detection of bone marrow lesions [13, 14], although in densely sclerotic lesions, where water content is low and susceptibility effects from calcified bone are present, its interpretation may be more questionable [15]. For this reason, European Society of Urogenital Radiology (ESUR) guidelines have recommended lower diffusion weightings in PCa [16] at the cost of reduced diffusion-weighted contrast.

Although the usage of the various "modern" imaging modalities has been the subject of trials in patients with advanced PCa [12, 17] and has been assessed for the evaluation of treatment responses in PCa [18], no comparative data between these modalities exist. The purpose of this study was to perform a prospective comparison of the diagnostic accuracy of ^{68}Ga-PSMA PET/CT, ^{18}NaF PET/CT and DW_{600}-MRI (the final method applied as per ESUR guidelines) for the detection of bone metastases in PCa patients with BCR.

Materials and methods

Design

A prospective, comparative study of the diagnostic characteristics of ^{68}Ga-PSMA PET/CT, ^{18}NaF PET/CT and DW_{600} MRI for the evaluation of bone metastases in patients with BCR after curatively intended treatment of PCa.

Patients

Patients with BCR after curatively intended treatment of PCa participated in this prospective study of ^{68}Ga PSMA PET/CT (EudraCT no.; 2014-005073-37) [19, 20]. Inclusion criteria were: 1) treatment with curative intent for PCa, 2) BCR based on two blood samples at least 2 weeks apart, 3) no ongoing androgen deprivation therapy (ADT) for more than a week before inclusion in the study, and 4) patients were included in the present comparative study of bone metastases if they had undergone at least two of the three index tests (^{68}Ga-PSMA PET/CT, ^{18}NaF PET/CT and/or a DW_{600}-MRI) for assessment of bone metastases. Consecutive patients from two urology departments were included in the study, and all of the study-related imaging was performed at one site; Aalborg University Hospital. MRI was conducted on the same day as one of the PET/CTs, whereas the order of the PET/CTs were random.

BCR was defined as suggested by the EAU guideline as a PSA level ≥ 0.2 ng/mL after radical prostatectomy, and a PSA level 2 ng/mL greater than the nadir PSA level for patients who had undergone radiation therapy [3].

^{68}PSMA-PET/CT

The PSMA ligand used in the study was ^{68}Ga-PSMA-11, which was synthesized as previously described [19]. Approximately 60 min before image acquisition, a bolus injection of 2 MBq/kg body weight (minimum 100 MBq, maximum 200 MBq) was given intravenously. All patients were examined using a VCT Discovery True 64 PET/CT system (GE Healthcare, USA). The scanned area covered the region from the base of the skull to the upper thigh, with 4 min per bed position. PET images were acquired in 3D mode and were reconstructed using attenuation correction, an ordered subset expectation maximization algorithm (128 × 128 matrix, 2 iterations, 24 subsets) and a Gauss filter of 6 mm. By default, a

low-dose CT was performed immediately after the PET scan. The ^{68}Ga-PSMA PET/CT was compliant with the recent guideline by European Association of Nuclear Medicine/Society of Nuclear Medicine on ^{68}Ga-PSMA PET/CT [21]; no intravenous furosemide prior to the PET/CT was used in the present study.

^{18}NaF-PET/CT

An^{18}NaF PET/CT scan was conducted in accordance with the Society of Nuclear Medicine guideline for ^{18}NaF PET/CT [22]. ^{18}NaF PET/CTs were performed with the same PET/CT scanner used for ^{68}Ga-PSMA PET/CT. Acquisition was performed 30 min after the intravenous administration of approximately 200 MBq in 3D mode covering the same anatomical area as the ^{68}Ga-PSMA PET/CT, and images were reconstructed using the same parameters.

CT

Low-dose CT was performed for attenuation correction and anatomical co-registration using the following parameters: 120 kV/10–150 mA and slice thickness 0.625 mm. In six patients, a contrast-enhanced diagnostic CT was performed using the above-mentioned parameters and a maximum of 100 mL (adjusted for kidney function) of Iomeron® 400 mg/mL (Bracco Imaging Scandinavia AB, Göteborg, Sweden).

MRI

MRI was performed on a 3T MRI scanner (Ingenia 3.0T, Philips Healthcare, Best, The Netherlands) using two anterior torso coils combined with a posterior coil. The combined coils allowed for a coverage of 120 cm, making it possible to scan the patient without moving the coils. The scan sequences followed the 2012 ESUR Prostate MRI Guidelines [16] (assessed March 2018) for evaluation of lymph nodes and bone metastases, which suggest using b values of 0 and 600 s/mm^2 (DW_{600}-MRI). The scan field included the pelvis and lumbar and thoracic spine. A minimum number of minor changes to the ESUR protocol were made to fit local procedures; parameters for DW_{600}-MRI, STIR and T1- and T2-weighted sequences are supplied in the supplementary file (Appendix 1). The DW images were subsequently reconstructed as whole-body 3D maximum intensity projection images. Quality assessment of the MRI (including DW_{600} images) was conducted after the first two patients and again after completion of the study.

Observers and procedure for image assessment

The ^{68}Ga-PSMA-PET/CT images were evaluated by three board-certified nuclear medicine physicians; two observers with a high level of experience in ^{68}Ga-PSMA PET/CT and one observer with an intermediate level of experience in PSMA according to the definition by Fendler et al. [23]. The evaluation of ^{68}Ga-PSMA PET/CT was conducted according to Rauscher et al. [24]. ^{18}F-NaF PET/CT was evaluated by two board-certified experienced nuclear medicine physicians (one observer with experience from more than 300 ^{18}F-NaF PET/CTs and the other observer with experience from more than 2000 ^{18}F-NaF PET/CTs). For the evaluation of the ^{18}F-NaF PET/CT, areas with increased ^{18}F-NaF-uptake were assessed and the low-dose CT was used for anatomical co-registration; e.g. increased ^{18}NaF uptake located around joints or in degenerative changes was considered benign. Finally, DW_{600}-MRI was evaluated together with T1-weighted images and fat-suppressed T2-images by two board-certified radiologists with at least 2 years of experience in reading whole-body DW-MRIs. Lesions hyperintense on DW_{600}-MRI, correlating with hyper-intense lesions on STIR and hypo-intense lesions on T1, were considered malignant.

For each of the imaging modalities, the observers were asked to categorize the patient using a three-point-scale: bone metastases present (M1), no bone metastases (M0) or equivocal in patients with bone lesions not typical for bone metastases. Additionally, observers provided a dichotomous answer (M0 or M1) on a patient level (secondary endpoint). Finally, the exact number and location of all metastatic lesions were described (in patients with more than 10 lesions, the exact localizations were not described). The observers had no access to the other imaging modality results or clinical information except for the PCa diagnosis with BCR after curatively intended treatment.

In general, the observers evaluated the images independently, then the individual evaluations within each imaging modality were compared. In cases of disagreement (either in the categorization or in the number of lesions), the readers re-evaluated the scans, and any disagreement was resolved by consensus.

Best valuable comparator

A histopathologic reference standard is rare, and frequently, is it not feasible to obtain in imaging of bone metastases for ethical reasons. Accordingly, a “best valuable comparator” (BVC) was defined for the presence or absence of bone metastases on a patient level. A BVC has been used in previous diagnostic studies of bone metastases [10, 11, 13, 25]. Moreover, any lesion described by at least one imaging modality was assessed to provide a BVC on a lesion level.

The BVC was based on all available imaging—previous, study-related imaging, supplementary imaging and follow-up imaging (^{68}Ga-PSMA PET/CT, ^{18}F-NaF PET/CT, ^{18}F-FDG PET/CT, anatomical MRI, DW_{600}-MRI, contrast-enhanced CT and bone scintigraphy), at least 12 months of clinical

follow-up and routine blood samples. Clinical data were retrieved from the case report forms and medical reports. Patients who received localized treatment such as salvage radiotherapy of the prostatic bed or lymph node dissection without any systemic anticancer treatment and subsequently had unmeasurable PSA levels (defined as < 0.1 ng/mL) were considered as being "true" negative for bone metastases. Physicians participating in the study (two nuclear medicine physicians, one radiologist and one urologist) from one site (Aalborg) evaluated the available information to define whether bone metastases were present, as well as the number and location of bone metastases. The BVC conclusions were accepted by all institutions.

Statistics

The results are summarized by their mean or median values, standard deviations and ranges. Patient-based analyses was performed using the BVC as the reference test. For each imaging modality, the sensitivity, specificity, positive predictive value (PPV) and negative predictive value (NPV) were calculated using data from all of the patients scanned by each modality. Performance of the methods was determined using receiver operating characteristic (ROC) curves; areas under the curve (AUCs) and 95% confidence intervals (95% CIs) for the AUCs were calculated. Sensitivity analyses were performed with equivocal lesions handled as non-metastatic ("optimistic" analysis) and with equivocal lesions handled as metastatic ("pessimistic" analysis). The AUCs for the three modalities were recomputed using only those patients investigated by all modalities and compared using a non-parametric test as suggested by DeLong et al. [26]. A simple logistic regression with equivocal scans (yes/no) as the outcome and modality as the explanatory variable was used to investigate whether some modalities produced more equivocal findings than others. Statistical analyses were performed using STATA®11 (StataCorp LP, College Station, TX, USA). All results are reported with 95% confidence intervals (CIs). Tests performed were two-sided and the significance level was set to 0.05.

Ethics

This study complied with the Helsinki II Declaration. All patients provided signed, informed consent to participate. The study protocol was approved by the North Denmark Region Committee on Health Research Ethics (N-20140080), the Danish Health and Medicine Authority and the Danish Data Protection Agency. The trial was registered in the EudraCT database (EudraCT no.; 2014–005073-37). In addition, the study was monitored by the Good Clinical Practice (GCP) unit at Aalborg and Aarhus University Hospitals, Denmark.

Results

Patients

Of the 69 patients included in this study, 1 was found to have lymphoma at the time of the study and consequently excluded from the analysis. The median PSA level at the time of the study was 0.4 ng/mL, and 65% of the patients (44/68) had a PSA level ≤ 1.0 ng/mL. Table 1 summarizes data for each treatment group. Sixty-six patients did not receive ADT for at least 6 months before the study or during the study, one patient had ADT for 1 week before study start and one patient received a waiver for inclusion due to 2 weeks of ADT treatment.

All patients were investigated by a ^{68}Ga-PSMA PET/CT scan ($n = 68$), 67 patients underwent a ^{18}NaF PET/CT scan (1 patient declined to travel twice for the scans) and 60 patients had a DW_{600}-MRI scan (the predominant reason for avoiding MRI was metal implants that were not compatible with MRI). The median time between the three investigations was 4 days, with 90% being done within 10 days (range 1 to 47 days).

A final consensus diagnosis of bone metastases was reached for every patient on the three-point scale and on the dichotomous scale by the observers for each of the study-related imaging modalities.

Best valuable comparator

Patients

It was possible to determine the presence or absence of bone metastasis in all patients (Fig. 1). A total of 10 patients (15%) with a median PSA 3.0 ng/mL were diagnosed with bone metastases (Table 2); 58 patients with a median PSA of 0.4 ng/mL did not have bone metastases (Fig. 1, Table 3). No patients who were diagnosed as M0 by the BVC at the time of the study developed bone metastases according to available follow-up imaging and clinical follow-up over 12 months.

Lesions

The number of metastatic bone lesions was evaluable in 9 of 10 patients categorized as M1 by the BVC, and a total of 16 lesions were diagnosed as bone metastases; one patient presented with 10+ rib lesions that were too numerous to evaluate.

Sixteen imaging-avid lesions (by at least one of the index tests) were classified as benign (details are provided in Table 3).

Patient-based analysis

^{68}Ga-PSMA PET/CT indicated bone metastases in 8 (12%) patients and equivocal findings in one patient (1%). ^{68}Ga-

Table 1 Demographic data of the study population

	Radical prostatectomy $N = 46$	Radical prostatectomy with later salvage radiotherapy $N = 17$	Radiotherapy $N = 5$
Age in years, mean ± SD (range)	67 ± 7.0 (47–80)	67 ± 7.0 (53–74)	70 ± 4.9 (64–77)
PSA at the time of the study, ng/mL, median (range)	0.4 (0.2–9.0)	1.1 (0.2–4.0)	4.5 (3.3–11)
PSA doubling time, months, median (range)[a]	7 (1.3–89)	12.3 (3.9–74)	9.6 (5.3–24)
Gleason, median (range)	7 (5–9)	7 (6–8)	7 (7–9)
M1 by best valuable comparator, n (%)	7 (15%)	2 (12%)	1 (20%)

SD standard deviation

[a] PSA doubling time was available in 51 patients, 14 patients were included in the study at the first PSA value>0.1 ng/mL after radical prostatectomy and 3 patients were included in the study at the first PSA value>0.1 ng/mL after radical prostatectomy followed by salvage radiotherapy of the prostatic bed

PSMA PET/CT correctly identified 8/10 patients with confirmed bone metastases, with no false positive patients (Table 4). ^{68}Ga-PSMA PET/CT was false negative in two patients (Table 2, patients 1 and 4). Two patients began ADT shortly before entering the study; none showed pathologic ^{68}Ga-PSMA uptake (both were declared M0 by the BVC). In addition, ^{68}Ga-PSMA PET/CT showed extraskeletal lesions suspicious of PCa metastases in 32 patients (data not shown).

^{18}F-NaF PET/CT diagnosed bone metastasis in 10 (15%) patients, whereas 5 (7%) patients were equivocal for bone metastases. ^{18}F-NaF PET/CT correctly identified 9/10 patients with bone metastases (Table 4). One patient had false positive results for bone metastases (Table 3, patient 11), and one patient had false negative results (Table 2, patient 3). All patients reported as equivocal by ^{18}F-NaF PET/CT or by ^{68}Ga-PSMA PET/CT were classified as M0 using the dichotomous scale. This was correct

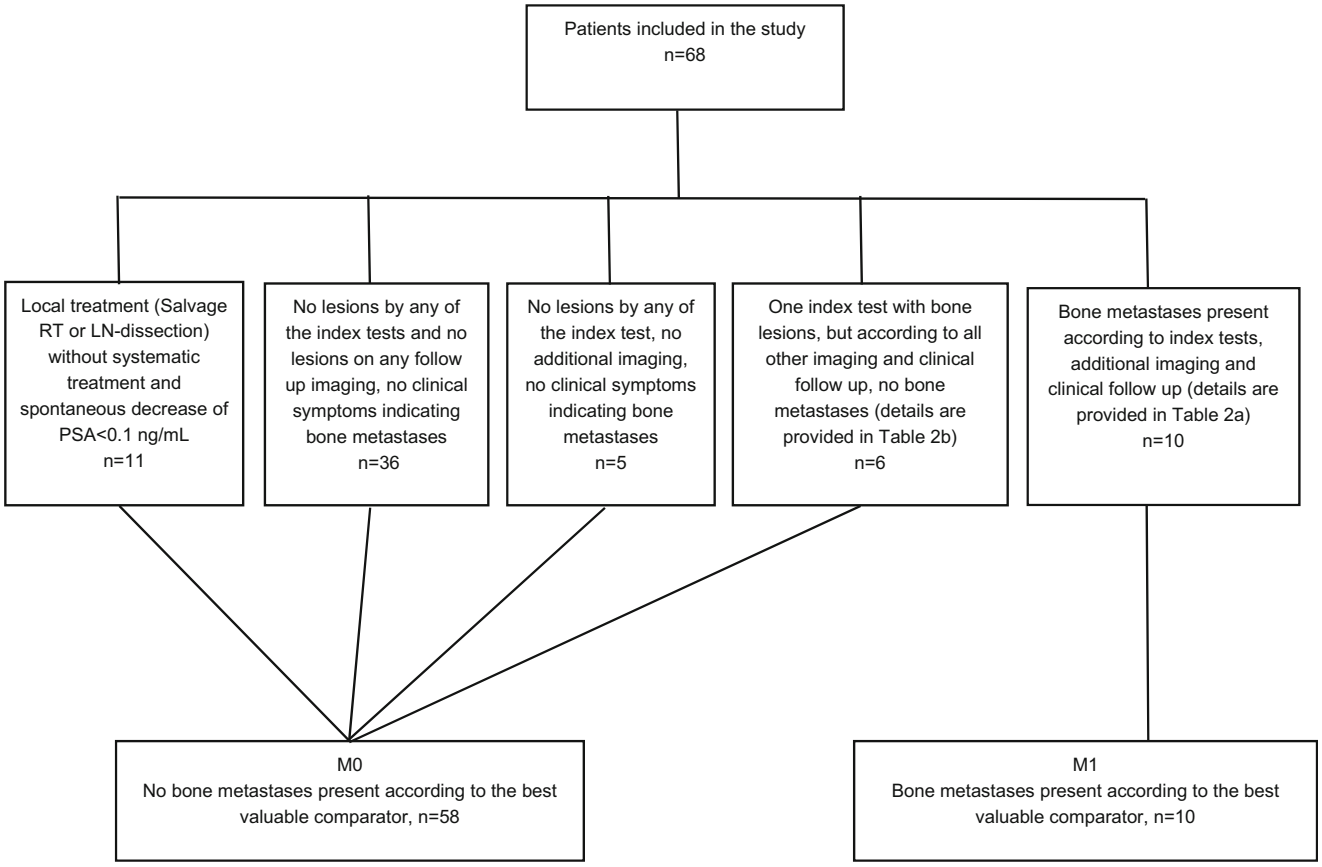

Fig. 1 Flowchart of patients for the assessment of the best valuable comparator

Table 2 Patients with bone metastases (M1) according to best valuable comparator in patients with at least one positive lesion by at least one imaging modality

Patient	Bone metastases according to BVC	PSA at the time of study	^{68}Ga-PSMA-PET/CT[a]	^{18}F-NaF-PET/CT[a]	DW_{600}-MRI[a]	Additional imaging before or after study-related procedures	Final diagnosis based upon the following findings in additional imaging and clinical follow-up
1	Th11: One BM	0.3 ng/mL	No bone lesions	Two bone lesions: Th11, left pubic bone	No DW-MRI	BS (including SPECT/CT) 12 months prior to study ceCT follow-up 3 months	Th11 right side: The lesion is seen and increasingly sclerotic at CT after start with ADT - > BM present. Left pubic bone: Bone scan including SPECT/CT 1 year prior (to prostatectomy) is with a small sclerotic lesion in the pelvis without tracer accumulation. CT morphology unchanged during 15 months from staging to follow-up 2 months after start on ADT - > not a BM
2	Right pubic bone: four small BM Left pubic bone: one BM	5.2 ng/mL	One bone lesion: right pubic bone	Three bone lesions: right pubic bone: two lesions, left pubic bone: one lesion	One bone lesion: Right pubic bone	Anatomical MRI ceCT	Right pubic bone: anatomical MRI and ceCT show four BM (closely situated). Left pubic bone one BM. Bone-related pain in the back and in the thighs. Have started ADT
3	Right side of C7: one BM	0.2 ng/mL	One bone lesion: C7	No bone lesions	No bone lesions (C7 is not included in the scan field of DW-MRI)	Anatomical MRI ldCT	Anatomical MRI confirms bone metastasis in C7. CT: cortical destruction of the right side of the lamina in C7
4	L4: one BM	1.1 ng/mL	No bone lesions	One bone lesion: L4	No DW-MRI	Anatomical MRI 7 years prior to the study, ceCT: 5 and 7 years prior to the study	Anatomical MRI and CT from 7 and 5 years prior to the study, respectively without any lesions in L4, at the time of the study a new sclerotic lesion have developed in L4.
5	Right pubic bone: one BM Left pubic bone: one BM	3.9 ng/mL	One bone lesion: right pubic bone	Four bone lesions: right pubic bone, left pubic bone, right iliac bone, left acetabulum	No bone lesions	Pre therapeutic anatomical MRI. Follow-up anatomical MRI	Anatomical MRI without lesions in os ilium and in the acetabulum. No CT-morphologic changes either (but arthrosis coxae)- > No BM Two lesions, one in each pubic bone present before radiation therapy and has incidentally been included in the radiation field of the prostate. Appear as partly radiated BM on follow up images (anatomical MRI).
6	Left pubic bone: one BM	3.2 ng/mL	One bone lesion: left pubic bone	One bone lesion: left pubic bone	No bone lesions	PSMA-PET/CT follow up 16 months, anatomical MRI	PSMA PET/CT after 16 months increasing sclerotic lesion in CT now without PSMA uptake (after stereotactic radiation). Anatomical MRI: BM in left pubic bone.
7	Ribs: multiple BM (10+). Both scapulas: one BM in each	0.4 ng/mL	Multiple bone lesions: ribs (5+), both scapulas	Multiple bone lesions: ribs (10+), both scapulas	Three bone lesions: both iliac bones L2 and L3:	Anatomical MRI ceCT	CT confirms the presence of multiple BM in several ribs. Anatomical MRI without BM in the spine or iliac bones (ribs not included in the scan field of anatomical MRI)

Table 2 (continued)

Patient	Bone metastases according to BVC	PSA at the time of study	^{68}Ga-PSMA-PET/CT[a]	^{18}F-NaF-PET/CT[a]	DW$_{600}$-MRI[a]	Additional imaging before or after study-related procedures	Final diagnosis based upon the following findings in additional imaging and clinical follow-up
					(ribs and scapula not included in the MR scan field)		
8	L1: one BM. Right iliac bone: one BM	3.0 ng/mL	Two bone lesions: L1, right iliac bone	Two bone lesions: L1, right iliac bone	No bone lesions	Anatomical MRI ldCT	Anatomical MRI and ldCT confirms the presence of two BM: L1, right iliac bone
9	Left pubic bone: one BM. Sacral bone: one BM	2.1 ng/ml	Two bone lesions: left pubic bone, sacral bone	Two bone lesions: left pubic bone, sacral bone	No bone lesions	Anatomical MRI ldCT	Anatomical MRI and ldCT confirms the presence of two BM in the left pubic bone and the sacral bone
10	4th right rib: one BM	3.2 ng/mL	One bone lesion: the 4th right rib	One bone lesion: the 4th right rib	No bone lesions (ribs not part of the MR scan field)	Anatomical MRI PSMA PET/CT follow up after 9 and 16 months	PSMA PET/CT 9 and 16 months: confirms BM in right 4th rib

BVC best valuable comparator, *BM* bone metastases, *LN* lymph nodes, *ceCT* contrast-enhanced CT, *ldCT* low-dose CT, *BS* bone scintigraphy, *SPECT/CT* Single-photon emission computed tomography, *ADT* androgen deprivation therapy

[a] Consensus diagnosis of independent observers (dichotomous scale)

according to the BVC and matched the "optimistic" sensitivity analysis results shown in Table 4.

According to the consensus diagnosis for DW$_{600}$-MRI, bone metastases were seen in six patients (10%), and four patients were equivocal for bone metastases (7%). Compared to the BVC-based results, DW$_{600}$-MRI correctly identified two of eight patients with bone metastases; four patients had false positive results (Table 4).

The scan field for DW$_{600}$-MRI included only the pelvis and the lumbar and thoracic spine; two patients had a single bone metastasis outside the area covered by DW$_{600}$-MRI according to the BVC, and an analysis taking the field of view into account was performed (Table 4). A thorough evaluation of the patients with false positive results is summarized in Table 3.

Four patients were deemed equivocal by DW$_{600}$-MRI, and using the dichotomous scale, one patient was categorized as M0 and three as M1. Compared to the BVC-based categorizations, this resulted in one patient with a false negative result (Table 2, patient 10) and three with false positive results (Table 3, patients 12, 13 and 16).

Of the 59 patients investigated by all modalities, uniform agreement for M0 was seen in 43 patients (73%), who were all classified as M0 by the BVC. Uniform agreement for M1 was seen in two patients (3.3%), with both classified as M1 by the BVC (Fig. 2). In two other patients (3.3%), a bone metastasis was seen outside the DW$_{600}$-MRI scanning field. Finally, conflicting categorizations from the three modalities were seen in 12 patients (20%), of whom 5 were M1 (Table 2, Fig. 3) and seven were M0 according to the BVC (Table 3). Accuracy of the imaging modalities, as calculated according to the AUC in the ROC analysis ($n = 59$), showed significant differences [AUC (95% CI): ^{68}Ga-PSMA-PET/CT, 1.0 (1.0–1.0); ^{18}NaF-PET/CT, 0.93 (0.80–1.0); and DW$_{600}$-MRI. 0.57 (0.40–0.73); $p < 0.001$]. When patients with a bone metastasis outside the DW$_{600}$-MRI scanning field were excluded, the accuracy, as calculated by the ROC analysis, remained significantly lower for DW$_{600}$-MRI than for PET/CT. This was also the case for both the "optimistic" and "pessimistic" analyses of equivocal patients.

No statistically significant difference ($p = 0.65$) was seen between ^{68}Ga-PSMA PET/CT and ^{18}NaF PET/CT for the detection of bone metastases as measured by the ROC analysis ($n = 67$); the AUC (95% CI) for ^{68}Ga-PSMA-PET/CT was 0.90 (0.77–1.0), and for ^{18}NaF-PET/CT, it was 0.94 (0.84–1.0).

There was no significant difference in the proportion of equivocal results between the modalities ($p = 0.17$).

Lesion-based analysis

A dichotomous consensus diagnosis was used for each of the three modalities. ^{68}Ga-PSMA PET/CT correctly identified 9 of 16 bone metastases, with no false positive lesions

Table 3 Patients without bone metastases (M0) according to best valuable comparator in patients with at least one positive lesion by at least one imaging modality

Patient number	PSA at the time of study	^{68}Ga-PSMA-PET/CT[a]	^{18}F-NaF-PET/CT[a]	DW_{600}-MRI[a]	Additional imaging before or after study-related procedures	Final diagnosis based upon the following findings in additional imaging and clinical follow-up
11	0.9 ng/mL	No bone lesions	One bone lesion: sacral bone	No bone lesions	Anatomical MRI BS + SPECT/CT follow up: 6 months	Anatomical MRI and CT morphology corresponds to compact bone (bone "island") low signal on both T1 and T2. BS + SPECT/CT follow-up after 6 months: no BM. LN dissection: removal of metastatic LN. No other anticancer treatment and PSA dropped to <0.1 ng/mL
12	0.5 ng/mL	No bone lesions	No NaF	Two bone lesions: right pubic bone, right iliac bone	ceCT 3 years prior to study and 18 months after the study Anatomical MRI	Right pubic bone: a lesion (cystic appearance) is present at ceCT 3 years prior to the study and unchanged 2 years after the study despite start of ADT treatment. Right iliac bone: no morphologic changes despite start of ADT
13	0.2 ng/mL	No bone lesions	No bone lesions	One bone lesion: T11	ceCT follow-up 18 months, Anatomical MR	ceCT 18 months: no BM, anatomical MR: no BM, salvage radiotherapy without systemic medical treatment, PSA dropped to <0.1 ng/mL
14	2.0 ng/mL	No bone lesions	No bone lesions	Two bone lesions: both iliac bones	Anatomical MRI follow-up 18 months, ceCT follow-up 12 months	Anatomical MRI 18 months: no BM, ceCT 12 months: no BM, no clinical symptoms indicating BM
15	0.8 ng/mL	No bone lesions	No bone lesions	One bone lesion: left pubic bone	Anatomical MRI, PSMA-PET/CT follow-up 11 months	Anatomical MRI: no BM PSMA-PET/ceCT, 11 months: no BM, PSA (23 months after the study) 2.3 ng/mL without any anticancer treatment and no clinical symptoms indicating BM
16	0.2 ng/mL	No bone lesions	No bone lesions	Four bone lesions: T5, T9, T12 and L3	Anatomical MRI PSMA PET/CT follow up 22 months	Anatomical MRI: no BM PSMA PET/CT (22 months): no BM, no clinical symptoms indicating BM and PSA = 1.2 ng/mL without any anticancer treatment for 20 months
17	0.2 ng/mL	No bone lesions	No bone lesions	Diffuse bone involvement in the entire skeleton	Anatomical MRI	Anatomical MRI: no BM, performance score 0 without any treatment and no clinical symptoms indicating BM. PSA = 0.2 ng/mL (after 19 months without treatment)
18	0.2 ng/mL	No bone lesions	No bone lesions	Two bone lesions: L3 and S2	Anatomical MRI PSMA PET/ceCT follow-up 19 months	Anatomical MRI: no BM, no anticancer treatment for 19 months, follow-up PSMA PET/CT: BM in right humerus, but no BM in L3 or S2.

BM Bone metastases, *LN* Lymph nodes, *ceCT* contrast enhanced CT, *BS* Bone scintigraphy, *SPECT* Single photon emission computed tomography, *ADT* Androgen deprivation therapy

[a] Consensus diagnosis of independent observers (dichotomous scale)

Table 4 Diagnostic properties and receiver operator characteristics for assessment of bone metastases by the index tests compared to the best valuable comparator on a patient level

Imaging modality	M1 by BVC			M0 by BVC			Sensitivity (95% CI)	Specificity (95% CI)	PPV (95% CI)	NPV (95% CI)	AUC (95% CI)
	M0	Equivocal	M1	M0	Equivocal	M1					
PSMA PET/CT ($n = 68$)	2	0	8	57	1	0	0.80 (0.44–0.98) *0.80 (0.44–0.98)*	1.00 (0.94–1.0) *0.98 (0.91–1.0)*	1.00 (0.63–1.0) *0.89 (0.52–1.0)*	0.97 (0.89–1.0) *0.97 (0.88–1.0)*	0.90 (0.89–1.0) *0.89 (0.76–1.0)*
NaF PET/CT ($n = 67$)	1	0	9	51	5	1	0.90 (0.56–1.0) *0.90 (0.56–1.0)*	0.98 (0.91–1.0) *0.90 (0.79–0.96)*	0.90 (0.56–1.0) *0.60 (0.32–0.84)*	0.98 (0.91–1.0) *0.98 (0.90–1.0)*	0.94 (0.84–1.0) *0.90 (0.79–1.0)*
DW-MRI (n = 60)	5	1	2	45	3	4	0.25 (0.03–0.65) *0.38 (0.09–0.76)*	0.92 (0.82–0.98) *0.87 (0.74–0.94)*	0.33 (0.04–0.78) *0.30 (0.07–0.65)*	0.89 (0.77–0.96) *0.90 (0.78–0.97)*	0.59 (0.42–0.75) *0.62 (0.44–0.81)*
DW-MRI (scan field-based, $n = 58$)	4	0	2	45	3	4	0.33 (0.04–0.78) *0.33 (0.04–0.78)*	0.92 (0.82–0.98) *0.87(0.74–0.94)*	0.33 (0.04–0.78) *0.22 (0.03–0.60)*	0.92 (0.82–0.98) *0.92 (0.80–0.98)*	0.63 (0.42–0.84) *0.60 (0.39–0.81)*

BVC best valuable comparator, *M0* no bone metastases, *M1* bone metastasis present, *Equivocal* the patient cannot be categorized as having bone metastasis or not. Optimistic analysis is considering equivocal as M0, pessimistic analysis is considering equivocal as M1 and written in italics. *PPV* positive predictive value, *NPV* negative predictive value, *AUC* area under the curve, *CI* confidence interval

(sensitivity, 56%; PPV, 100%), whereas ^{18}NaF PET/CT identified 13 of 16 lesions, with 4 false positive lesions (sensitivity, 81%; PPV, 76%) (Fig. 4). DW_{600}-MRI identified 3 of 12 lesions but with another 12 false positive lesions (sensitivity, 25%; PPV, 20%). Additionally, DW_{600}-MRI categorized one patient with diffuse metastatic involvement of the skeleton—BVC deemed the patient to be M0 (patient 7, Table 3).

The patient with 10+ metastases according to the BVC had two metastases in the scapula and at least 5 certain metastases in the ribs by ^{68}Ga PSMA PET/CT, and ^{18}NaF PET/CT diagnosed the two scapular metastases and 10+ rib metastases. DW_{600}-MRI also categorized this patient as M1, but based on completely different lesions in the spine that were not seen with the two other modalities. The lesions in the spine were non-metastatic according to the BVC.

Discussion

The present comparative is, to the best of our knowledge, the first prospective study to directly compare the diagnostic properties of ^{68}Ga-PSMA PET/CT to those of ^{18}NaF PET/CT and DW_{600}-MRI in assessing bone metastases using a homogeneous group of patients with BCR and low PSA levels. A key finding was an excellent diagnostic accuracy for the assessment of bone metastases by both ^{68}Ga-PSMA PET/CT and ^{18}NaF PET/CT, but significantly worse diagnostic characteristics of DW_{600}-MRI performed according to ESUR guidelines for bone lesions.

^{68}Ga-PSMA PET/CT has previously shown excellent detection rates in patients with BCR [6], but only a single study has evaluated ^{68}Ga-PSMA PET/CT specifically for bones [10, 27]. Pyka et al. demonstrated a sensitivity of 95–99% and a specificity of 88–98% with optimistic and pessimistic analyses for the evaluation of bone metastases in BCR on a patient level [10]. Their specificity was comparable to our findings, whereas their sensitivity was slightly higher. The difference in sensitivity may be PET-related; we used a relatively old PET scanner without a time-of-flight or point spread function in our PET/CT imaging, which is known to increase the signal-to-noise ratio and image quality [28] and has been applied in previous studies [10].

The high sensitivity of ^{18}NaF PET/CT has been shown in other studies of bone metastases in PCa patients [14, 29], in populations with mixed cancers [11] and in systematic reviews [30]. These studies reported somewhat lower specificities, from 54% in the assessment of spine metastases when compared to MRI [29] to specificities of approximately 70–80% [31, 32]. Our sensitivity is in line with data in the existing literature, though we demonstrate a high specificity, which is similar to a recent study comparing ^{18}NaF PET/CT to bone scintigraphy by Löfgren et al. [11]. In our study, ^{18}NaF PET/CT revealed one patient with false positive results and a total

of four false positive lesions; this was due to benign lesions being interpreted as malignant.

In contrast, DW_{600}-MRI exhibited a low sensitivity and modest specificity. The diagnostic accuracy of DW_{600}-MRI was significantly lower than that of ^{68}Ga-PSMA PET/CT and ^{18}NaF PET/CT and was much lower than reported in previous studies applying DW-MRI for the assessment of bone metastases [13, 14]. Exclusion of the two patients with bone metastases outside the DW_{600}-MRI scanning field did not eliminate the significant difference between DW_{600}–MRI and PET/CT. In particular, a high number of false positive findings was seen. A thorough evaluation and follow up of the patients with false positive results revealed no clinical signs of bone metastases or metastases according to additional imaging despite the fact that none of the patients received any anticancer treatment during the follow-up period.

The diagnostic performance of DW_{600}-MRI was low when compared to results from previous studies evaluating DW-MRI for the detection of bone metastases [13, 14, 33, 34] and likely reflects the choice of diffusion weighting. The acquisition parameters in the present study were based on the latest guideline by ESUR for lymph nodes and bone metastases at the time of protocol development [16] in order to attain standardized settings; the guideline remains the official guideline from a radiologic society today. The low b value is likely to account for the low sensitivity (33%) of our results. The b value of 600 used by Nakanishi et al. [34] in a study of 30 patients, of whom only 17 had PCa, reported a sensitivity of 98%, and the results reflect a different population largely without sclerotic metastases.

The use of DW-MRI for tumour staging in primary PCa has been strongly debated owing to challenges with image acquisition, quality and interpretation standardization, and some of these challenges have been partly addressed by the ESUR guidelines [16], which have recently been expanded [35]. In the present study, the observers analysing the DW_{600}-MRI images were experienced in interpreting DW-MRI images, but the lack of a high b value to provide sufficient diffusion-weighted contrast resulted in discrepancies in readings that required a consensus resolution in a third of the cases. Review and appropriate revision of the ESUR guideline is therefore warranted. Moreover, the imaging acquisition was done at a separate center without input from the radiologists reading the images into the data acquisition parameters, nor was there any ongoing quality control of the images obtained. Setting up DW-MRI sequence collection for assessing PCa requires more control of the image acquisition methodology than does setting up PSMA PET/CT or ^{18}F-NaF PET/CT from scratch. Since the first reports on ^{68}Ga-PSMA PET/CT in 2012 [36, 37], its use has been implemented in numerous institutions across Europe and Asia, whereas the use of whole-body DW-MRI for assessments of bone metastases has been confined to few dedicated centers over the same time span because strict quality assurance and quality control measures are essential to achieve data that can be interpreted meaningfully.

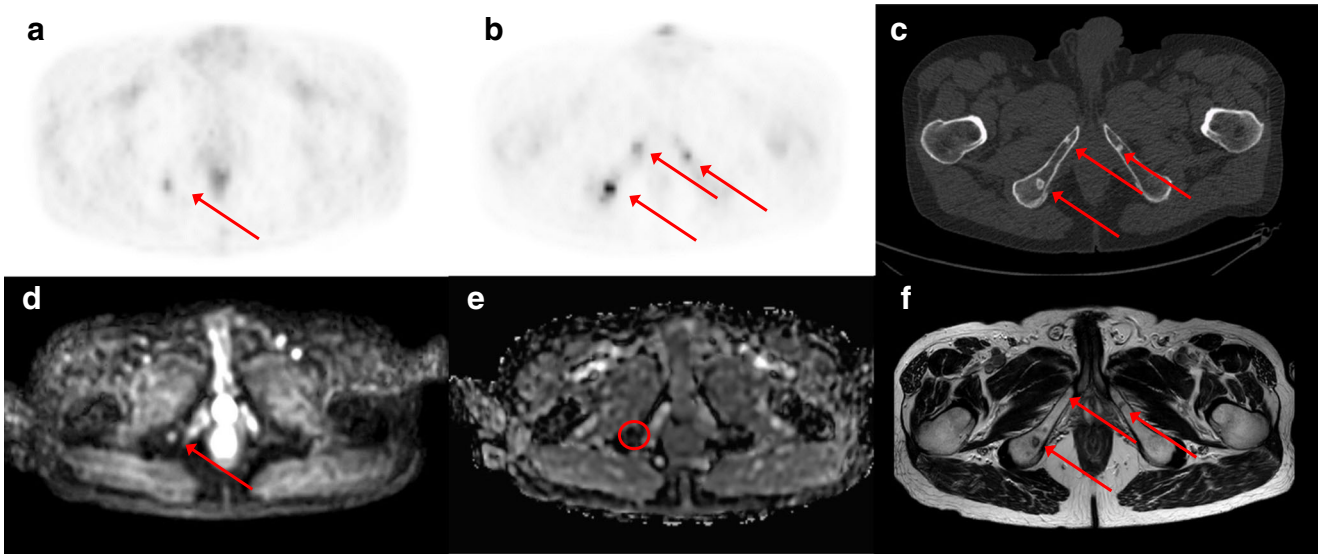

Fig. 2 Example of a patient with bone metastases in the pelvis according to the study-related modalities and the BVC (PSA 5.2 ng/mL at the time of the study, BCR after prostatectomy, Table 2, patient 2): one bone metastases is present in the left pubic bone and two in the right pubic bone (in the field of view shown). There was excellent concordance on a patient level by the three study-related modalities. ^{68}Ga-PSMA PET/CT (**a**) shows markedly increased uptake in the posterior lesion in the right pubic bone (*arrow*) but no increased uptake in the other metastases. ^{18}F-NaF PET/CT shows increased uptake in all metastases (*arrows*). The corresponding CT image (**c**) shows the mixed sclerotic/osteolytic bone metastases (*arrows*). On DW_{600}-MRI, only the lesion in the right pubic bone was detected as a focal high-intensity lesion (*arrow*) on the native diffusion-weighted (b600) image (**d**), correlating with a low signal on the associated apparent diffusion coefficient (ADC) map (*arrow*; **e**), confirming this is indeed a bone metastasis. The metastases in the left pubic bone were not detected. The corresponding anatomical MRI, T2-weighted image (**f**) shows the three bone metastases (*arrows*)

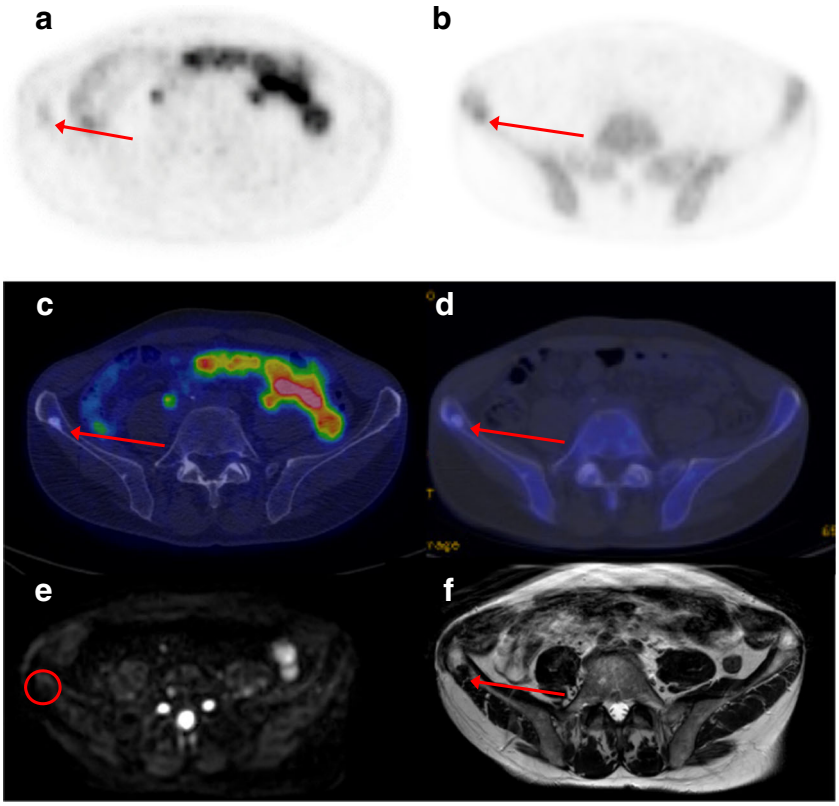

Fig. 3 Example of a patient with bone metastases in the right iliac bone according to the BVC (PSA 3.0 ng/mL at the time of the study, previous radical prostatectomy and salvage radiotherapy, Table 2, patient 8): Discordant findings was seen between study-related imaging modalities: ^{68}Ga-PSMA PET (**a**) and ^{18}F-NaF PET (**b**) show increased uptake in the right iliac bone (*arrow*), and a sclerotic lesion is seen in the corresponding CT image fused with ^{68}Ga-PSMA PET (**c**) and fused with ^{18}F-NaF PET (**d**), whereas the diffusion weighted (b600) image shows no increased signal in this area as shown by the circle (**e**). The corresponding T2-weighted image (**f**) shows a bone metastasis in the right iliac bone (*arrow*)

The strengths of the present study lie in the prospective design with its inherent data completeness. The population constituted a very homogeneous group of patients with BCR after curatively intended treatment of PCa, with more than two thirds of the patients having PSA levels < 1 ng/mL. Moreover, the majority of PSMA PET/CT studies in patients with BCR have included patients receiving ADT. Currently, the impact of ADT on PSMA-ligand PET/CT has not been finally evaluated. The vast majority of patients in this study did not receive ADT.

A BVC was chosen as the reference standard as bone biopsy of every lesion seen in any of the investigations was not acceptable for ethical and logistical reasons, and random bone biopsies in patients without lesions to verify the lack of metastases were also not warranted. BVCs have been applied in similar studies previously [10, 11, 13], but it is of utmost importance to keep the intrinsic verification bias in mind as only lesions seen by the index tests can be properly evaluated [12]. We strived to render the decisions behind determining the BVC transparent (Fig. 1, Tables 2 and 3). Eleven patients experienced a fall in PSA level to < 0.1 ng/mL following local treatment of the prostatic bed or lymph node dissection and were consequently diagnosed without bone metastases. The presence or absence of bone metastases in the remaining

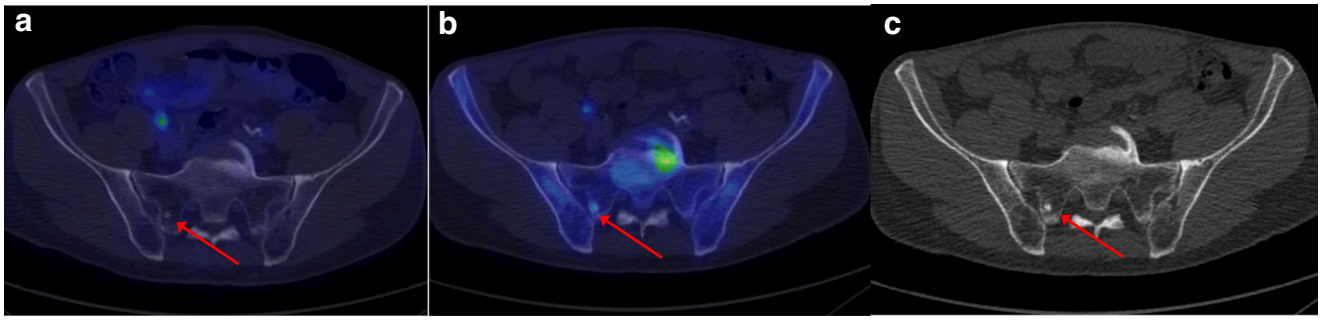

Fig. 4 Example of a patient without bone metastases according to the BVC (PSA 0.9 ng/mL at the time of the study, BCR after prostatectomy, Table 3, patient 11): The patient underwent lymph node dissection of the pelvis, with removal of a lymph node metastasis, followed by a spontaneous decrease in PSA level to < 0.1 ng/mL. Follow-up imaging (anatomical MRI and bone scan including SPECT/CT) verified the M0 status. Discordant findings were seen between the study-related imaging modalities: ^{68}Ga-PSMA PET/CT (**a**) showed no PSMA uptake, whereas ^{18}F-NaF PET/CT (**b**) showed increased uptake (false positive) in a sclerotic lesion in the sacral bone (*arrow*). The corresponding CT image is shown in (**c**)

patients was confirmed by clinical follow-up over 12–24 months. In all but five patients (Fig. 1), the BVC was based on two different anatomical modalities (CT and anatomical MRI), and at least two of the three different functional imaging modalities provide information about the bones; PSMA (which is specifically bound to the cellular membrane in PCa-cells); NaF (which is a taken up in areas with increased bone turnover, thus indicating the bone reaction secondary to metastasis); and DW-MRI (which depends on the random motion of water molecules, enabling detection of bone metastases before any bone remodelling has occurred) [13].

According to the European guidelines, bone scintigraphy should not be performed in patients with BCR until the PSA level reaches 10 ng/mL [3]. In the present study, we mostly included (> 90%) patients with a PSA level ≤ 1.0 ng/mL, and 15% of the patients had bone metastases according to the BVC. This finding is in line with previous retrospective studies [38]. Calais et al. reported 23 patients (9%) with bone metastases according to ^{68}Ga-PSMA PET/CT among 270 patients with BCR and a PSA level ≤ 1.0 ng/mL after radical prostatectomy [9]. ^{68}Ga-PSMA PET/CT has the inherent advantage of visualizing local recurrence, as well as lymph node and soft tissue metastases [39].

A complete sensitivity analysis on a lesion level was not performed since the small number of patients with a large number of lesions would strongly affect the analysis; this is because defining the number of true negative lesions is complex and because treatment with curative intent is decided at a patient level rather than at a lesion level.

This comparative study assessed three novel imaging methodologies for the assessment of bone lesion at BCR. Similar comparative studies are warranted in other settings, e.g., staging in high-risk patients and for the assessment of treatment responses in metastatic castration-resistant PCa. We know from recent studies that apparent similar methods like bone scans and ^{18}NaF PET/CT may show conflicting data for the assessment of treatment responses in PCa [40].

Conclusion

In the present prospective head-to-head comparison of ^{68}Ga-PSMA PET/CT, ^{18}NaF PET/CT and DW_{600}-MRI in PCa patients with BCR, both ^{68}Ga-PSMA PET/CT and ^{18}NaF PET/CT showed comparable and high diagnostic accuracies for the detection of bone metastases and performed significantly better than DW_{600}-MRI, where the diffusion-weighted contrast, as recommended by the ESUR, was inadequate to distinguish bone metastases. ^{68}Ga-PSMA PET/CT has the advantage over ^{18}NaF PET/CT of visualizing bone as well as soft-tissue lesions and thus should be used for localization of metastases in patients with BCR.

Funding This study was supported by unrestricted grants from the Obel Family Foundation and the Danielsen foundation.

Compliance with ethical standards

Conflict of interest HDZ received grant funding from the Danielsen Foundation, NdS receives grant funding from Cancer Research UK, KDP is a Cancer Research UK funded fellow and LJP receives grant foundation form the Obel Family Foundation. The authors have no other conflicts of interest regarding the present manuscript.

Ethical approval All procedures performed in studies involving human participants were in accordance with the ethical standards of the institutional and/or national research committee and with the 1964 Helsinki Declaration and its later amendments or comparable ethical standards.

References

1. Suardi N, Porter CR, Reuther AM, Walz J, Kodama K, Gibbons RP, et al. A nomogram predicting long-term biochemical recurrence after radical prostatectomy. Cancer. 2008;112:1254–63. https://doi.org/10.1002/cncr.23293.
2. Cornford P, Bellmunt J, Bolla M, Briers E, De Santis M, Gross T, et al. EAU-ESTRO-SIOG guidelines on prostate cancer. Part II: treatment of relapsing, metastatic, and castration-resistant prostate cancer. Eur Urol. 2017;71:630–42. https://doi.org/10.1016/j.eururo.2016.08.002.
3. Heidenreich A, Bastian PJ, Bellmunt J, Bolla M, Joniau S, van der Kwast T, et al. EAU guidelines on prostate cancer. Part II: treatment of advanced, relapsing, and castration-resistant prostate cancer. Eur Urol. 2014;65:467–79.
4. Schweizer MT, Zhou XC, Wang H, Yang T, Shaukat F, Partin AW, et al. Metastasis-free survival is associated with overall survival in men with PSA-recurrent prostate cancer treated with deferred androgen deprivation therapy. Ann Oncol. 2013;24:2881–6. https://doi.org/10.1093/annonc/mdt335.
5. Norgaard M, Jensen AO, Jacobsen JB, Cetin K, Fryzek JP, Sorensen HT. Skeletal related events, bone metastasis and survival of prostate cancer: a population based cohort study in Denmark (1999 to 2007). J Urol. 2010;184:162–7.
6. Afshar-Oromieh A, Holland-Letz T, Giesel FL, Kratochwil C, Mier W, Haufe S, et al. Diagnostic performance of (68)Ga-PSMA-11 (HBED-CC) PET/CT in patients with recurrent prostate cancer: evaluation in 1007 patients. Eur J Nucl Med Mol Imaging. 2017;44:1258–68. https://doi.org/10.1007/s00259-017-3711-7.
7. Eiber M, Maurer T, Souvatzoglou M, Beer AJ, Ruffani A, Haller B, et al. Evaluation of hybrid (6)(8)Ga-PSMA ligand PET/CT in 248 patients with biochemical recurrence after radical prostatectomy. J Nucl Med. 2015;56:668–74. https://doi.org/10.2967/jnumed.115.154153.
8. Afshar-Oromieh A, Avtzi E, Giesel FL, Holland-Letz T, Linhart HG, Eder M, et al. The diagnostic value of PET/CT imaging with the (68)Ga-labelled PSMA ligand HBED-CC in the diagnosis of recurrent prostate cancer. Eur J Nucl Med Mol Imaging. 2015;42:197–209. https://doi.org/10.1007/s00259-014-2949-6.
9. Calais J, Czernin J, Cao M, Kishan AU, Hegde JV, Shaverdian N, et al. (68)Ga-PSMA PET/CT mapping of prostate cancer biochemical recurrence following radical prostatectomy in 270 patients with PSA<1.0ng/ml: impact on salvage radiotherapy planning. J Nucl Med. 2017; https://doi.org/10.2967/jnumed.117.201749.
10. Pyka T, Okamoto S, Dahlbender M, Tauber R, Retz M, Heck M, et al. Comparison of bone scintigraphy and 68Ga-PSMA PET for

skeletal staging in prostate cancer. Eur J Nucl Med Mol Imaging. 2016; https://doi.org/10.1007/s00259-016-3435-0.

11. Lofgren J, Mortensen J, Rasmussen SH, Madsen C, Loft A, Hansen AE, et al. A prospective study comparing 99mTc-HDP planar bone scintigraphy and whole-body SPECT/CT with 18F-fluoride PET/CT and 18F-fluoride PET/MRI for diagnosing bone metastases. J Nucl Med. 2017; https://doi.org/10.2967/jnumed.116.189183.
12. Padhani AR, Lecouvet FE, Tunariu N, Koh DM, De Keyzer F, Collins DJ, et al. Rationale for modernising imaging in advanced prostate cancer. European Urology Focus. 2017;3:223–39. https://doi.org/10.1016/j.euf.2016.06.018.
13. Lecouvet FE, El MJ, Collette L, Coche E, Danse E, Jamar F, et al. Can whole-body magnetic resonance imaging with diffusion-weighted imaging replace Tc 99m bone scanning and computed tomography for single-step detection of metastases in patients with high-risk prostate cancer? Eur Urol. 2012;62:68–75.
14. Mosavi F, Johansson S, Sandberg DT, Turesson I, Sorensen J, Ahlstrom H. Whole-body diffusion-weighted MRI compared with (18)F-NaF PET/CT for detection of bone metastases in patients with high-risk prostate carcinoma. AJR Am J Roentgenol. 2012;199:1114–20. https://doi.org/10.2214/ajr.11.8351.
15. Eiber M, Holzapfel K, Ganter C, Epple K, Metz S, Geinitz H, et al. Whole-body MRI including diffusion-weighted imaging (DWI) for patients with recurring prostate cancer: technical feasibility and assessment of lesion conspicuity in DWI. Journal of Magnetic Resonance Imaging : JMRI. 2011;33:1160–70. https://doi.org/10.1002/jmri.22542.
16. Barentsz JO, Richenberg J, Clements R, Choyke P, Verma S, Villeirs G, et al. ESUR prostate MR guidelines 2012. Eur Radiol. 2012;22:746–57. https://doi.org/10.1007/s00330-011-2377-y.
17. Larbi A, Dallaudiere B, Pasoglou V, Padhani A, Michoux N, Vande Berg BC, et al. Whole body MRI (WB-MRI) assessment of metastatic spread in prostate cancer: therapeutic perspectives on targeted management of oligometastatic disease. Prostate. 2016;76:1024–33. https://doi.org/10.1002/pros.23196.
18. Lecouvet FE, Talbot JN, Messiou C, Bourguet P, Liu Y, de Souza NM. Monitoring the response of bone metastases to treatment with magnetic resonance imaging and nuclear medicine techniques: a review and position statement by the European Organisation for Research and Treatment of Cancer imaging group. European Journal of Cancer (Oxford, England : 1990). 2014;50:2519–31. https://doi.org/10.1016/j.ejca.2014.07.002.
19. Nielsen JB, Zacho HD, Haberkorn U, Nielsen KM, Dettmann K, Langkilde NC, et al. A comprehensive safety evaluation of 68Ga-labeled ligand prostate-specific membrane antigen 11 PET/CT in prostate cancer: the results of 2 prospective, multicenter trials. Clin Nucl Med. 2017;42:520–4. https://doi.org/10.1097/rlu.0000000000001681.
20. Zacho HD, Nielsen JB, Haberkorn U, Nielsen KM, Dettmann K, Langkilde NC, et al. 68Ga-PSMA PET/CT in patients with biochemical recurrence of prostate cancer: a prospective, two-center study. Clin Nucl Med. 2018.
21. Fendler WP, Eiber M, Beheshti M, Bomanji J, Ceci F, Cho S, et al. 68Ga-PSMA PET/CT: joint EANM and SNMMI procedure guideline for prostate cancer imaging: version 1.0. Eur J Nucl Med Mol Imaging. 2017;44:1014–24. https://doi.org/10.1007/s00259-017-3670-z.
22. Segall G, Delbeke D, Stabin MG, Even-Sapir E, Fair J, Sajdak R, et al. SNM practice guideline for sodium 18F-fluoride PET/CT bone scans 1.0. J Nucl Med. 2010;51:1813–20.
23. Fendler WP, Calais J, Allen-Auerbach M, Bluemel C, Eberhardt N, Emmett L, et al. 68Ga-PSMA-11 PET/CT interobserver agreement for prostate cancer assessments: an international multicenter prospective study. J Nucl Med. 2017; https://doi.org/10.2967/jnumed.117.190827.
24. Rauscher I, Maurer T, Fendler WP, Sommer WH, Schwaiger M, Eiber M. (68)Ga-PSMA ligand PET/CT in patients with prostate cancer: how we review and report. Cancer Imaging: the Official Publication of the International Cancer Imaging Society. 2016;16:14. https://doi.org/10.1186/s40644-016-0072-6.
25. Fonager RF, Zacho HD, Langkilde NC, Fledelius J, Ejlersen JA, Haarmark C, et al. Diagnostic test accuracy study of (18)F-sodium fluoride PET/CT, (99m)Tc-labelled diphosphonate SPECT/CT, and planar bone scintigraphy for diagnosis of bone metastases in newly diagnosed, high-risk prostate cancer. American Journal of Nuclear Medicine and Molecular Imaging. 2017;7:218–27.
26. DeLong ER, DeLong DM, Clarke-Pearson DL. Comparing the areas under two or more correlated receiver operating characteristic curves: a nonparametric approach. Biometrics. 1988;44:837–45.
27. Zacho HD, Nielsen JB, Haberkorn U, Stenholt L, Petersen LJ. (68)Ga-PSMA PET/CT for the detection of bone metastases in prostate cancer: a systematic review of the published literature. Clin Physiol Funct Imaging. 2017; https://doi.org/10.1111/cpf.12480.
28. Akamatsu G, Ishikawa K, Mitsumoto K, Taniguchi T, Ohya N, Baba S, et al. Improvement in PET/CT image quality with a combination of point-spread function and time-of-flight in relation to reconstruction parameters. J Nucl Med. 2012;53:1716–22. https://doi.org/10.2967/jnumed.112.103861.
29. Poulsen MH, Petersen H, Hoilund-Carlsen PF, Jakobsen JS, Gerke O, Karstoft J, et al. Spine metastases in prostate cancer: comparison of [Tc]MDP wholebody bone scintigraphy, [F]choline PET/CT, and [F]NaF PET/CT. BJU Int. 2014;114(6):818–23. https://doi.org/10.1111/bju.12599.
30. Wondergem M, van der Zant FM, van der Ploeg T, Knol RJJ. A literature review of 18 F-fluoride PET/CT and 18 F-choline or 11 C-choline PET/CT for detection of bonemtastases in patients with prostate cancer. Nucl Med Commun. 2013;34:935–45.
31. Damle NA, Bal C, Bandopadhyaya GP, Kumar L, Kumar P, Malhotra A, et al. The role of 18F-fluoride PET-CT in the detection of bone metastases in patients with breast, lung and prostate carcinoma: a comparison with FDG PET/CT and 99mTc-MDP bone scan. Jpn J Radiol. 2013;31:262–9. https://doi.org/10.1007/s11604-013-0179-7.
32. Iagaru AH, Mittra E, Colletti PM, Jadvar H. Bone-targeted imaging and radionuclide therapy in prostate cancer. J Nucl Med. 2016;57:19s–24s. https://doi.org/10.2967/jnumed.115.170746.
33. Gutzeit A, Doert A, Froehlich JM, Eckhardt BP, Meili A, Scherr P, et al. Comparison of diffusion-weighted whole body MRI and skeletal scintigraphy for the detection of bone metastases in patients with prostate or breast carcinoma. Skelet Radiol. 2010;39:333–43.
34. Nakanishi K, Kobayashi M, Nakaguchi K, Kyakuno M, Hashimoto N, Onishi H, et al. Whole-body MRI for detecting metastatic bone tumor: diagnostic value of diffusion-weighted images. Magnetic Resonance in Medical Sciences : MRMS : an Official Journal of Japan Society of Magnetic Resonance in Medicine. 2007;6:147–55.
35. Padhani AR, Lecouvet FE, Tunariu N, Koh DM, De Keyzer F, Collins DJ, et al. METastasis reporting and data system for prostate cancer: practical guidelines for acquisition, interpretation, and reporting of whole-body magnetic resonance imaging-based evaluations of multiorgan involvement in advanced prostate cancer. Eur Urol. 2017;71:81–92. https://doi.org/10.1016/j.eururo.2016.05.033.
36. Afshar-Oromieh A, Haberkorn U, Eder M, Eisenhut M, Zechmann CM. [68Ga]Gallium-labelled PSMA ligand as superior PET tracer for the diagnosis of prostate cancer: comparison with 18F-FECH. Eur J Nucl Med Mol Imaging. 2012;39:1085–6.
37. Afshar-Oromieh A, Malcher A, Eder M, Eisenhut M, Linhart HG, Hadaschik BA, et al. PET imaging with a [68Ga]gallium-labelled PSMA ligand for the diagnosis of prostate cancer: biodistribution in humans and first evaluation of tumour lesions. Eur J Nucl Med Mol

Imaging. 2013;40:486–95. https://doi.org/10.1007/s00259-012-2298-2.

38. Verburg FA, Pfister D, Heidenreich A, Vogg A, Drude NI, Voo S, et al. Extent of disease in recurrent prostate cancer determined by [(68)Ga]PSMA-HBED-CC PET/CT in relation to PSA levels, PSA doubling time and Gleason score. Eur J Nucl Med Mol Imaging. 2016;43:397–403. https://doi.org/10.1007/s00259-015-3240-1.
39. Afshar-Oromieh A, Zechmann CM, Malcher A, Eder M, Eisenhut M, Linhart HG, et al. Comparison of PET imaging with a (68)Ga-labelled PSMA ligand and (18)F-choline-based PET/CT for the diagnosis of recurrent prostate cancer. Eur J Nucl Med Mol Imaging. 2014;41:11–20. https://doi.org/10.1007/s00259-013-2525-5.
40. Fonager RF, Zacho HD, Langkilde NC, Fledelius J, Ejlersen JA, Hendel HW, et al. Prospective comparative study of (18)F-sodium fluoride PET/CT and planar bone scintigraphy for treatment response assessment of bone metastases in patients with prostate cancer. Acta Oncol. 2018:1–7. https://doi.org/10.1080/0284186x.2018.1438651.